

SYNAPSE

Volume one | Issue one

Register to receive *Synapse* electronically at mercyneuro.org.

New Hope for Patients with Wide-Neck Aneurysms

George Luh, MD

Up to one in 15 people in the United States will develop a brain aneurysm. Over 30,000 of these people will suffer subarachnoid hemorrhages each year. Ten to 15 percent of these patients will die before reaching the hospital and over 50 percent will die within the first 30 days following subarachnoid hemorrhage. Of those who survive, about half will suffer some sort of permanent neurologic deficit. Brain aneurysms can occur at any age and are more common in females with a 3:2 female to male ratio. The most common age at presentation is 35 to 60 years of age.

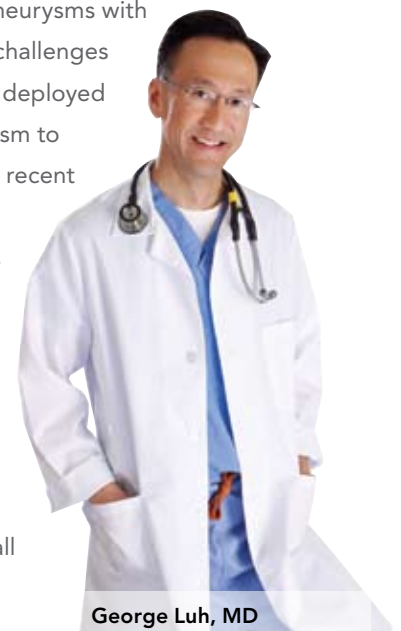Whether or not an aneurysm is amenable to endovascular therapy depends on the size, shape, and location of the aneurysm within the brain.

Treatment options for brain aneurysms include surgical clipping and endovascular therapy. The ISAT (International Subarachnoid Aneurysm Trial) study was an international multi-center prospective randomized trial of over 2,100 patients comparing surgical clipping with endovascular

coiling. The results showed an absolute risk reduction of 7 percent (and a relative risk reduction of 23 percent) in favor of endovascular coiling.

Nevertheless, not all aneurysms are amenable to endovascular therapy. Brain aneurysm treatment requires a team approach. It is important to seek treatment at hospitals where both surgical clipping (performed by a neurovascular neurosurgeon) and endovascular therapy (performed by an interventional neuroradiologist) are available. Interestingly, over 75 percent of patients in the United States with subarachnoid hemorrhage are admitted to hospitals where interventional neuroradiology services are not available.

Whether or not an aneurysm is amenable to endovascular therapy depends on the size, shape, and location of the aneurysm within the brain. Aneurysms with a wide neck present difficult challenges to coiling and often a stent is deployed across the neck of the aneurysm to help hold the coils in place. A recent advance in the endovascular treatment of brain aneurysms involves filling the aneurysm with a liquid embolic material called Onyx HD500. Onyx HD500 is a HUD (Humanitarian Use Device) approved for the treatment of intracranial saccular sidewall aneurysms with a wide neck



George Luh, MD

continued on page 3

Letter from the Editor

John Schafer, MD

Welcome. Members of the medical community are well aware of the multitude of advances in medical care in recent decades which result from progress in diagnosis and treatment. And in the field of the neurosciences, the breakthroughs have been significant.

Two articles in this inaugural issue of *Synapse* describe remarkable advances in treatment of cerebral vascular anomalies using endovascular techniques which in the past would have required surgery, or would simply have gone untreated because surgical risk could outweigh benefit.

In the past two decades, medical treatments have for the first time become available for acute stroke, Alzheimer’s disease, multiple sclerosis and some movement disorders. Treatments for migraine, epilepsy, sleep disorders and Parkinson’s disease have improved with increasing armamentaria of pharmacologic and surgical therapies.

As treatments become available, accuracy of diagnosis has become increasingly important. For example, identifying subtypes of stroke and differentiating stroke from “stroke mimics,” such as seizures or migraine, used to be no more than an academic exercise. With the advent of tPA, rapid and correct diagnosis of stroke has become a crucial part of emergency medical care and has resulted in sophisticated protocols, stroke teams and stroke centers. Similarly, while diagnosis of multiple sclerosis used to be an intellectual exercise leading to no therapeutic solutions, a number of treatments have become available that, for the first time, alter the course of this often devastating disease. With

the discovery that the greatest benefits to patients are achieved by initiating treatments as early as possible, the need for early and accurate diagnosis has become critical. This need has given rise to the development of multiple sclerosis centers, where patients can be seen expediently and important decisions about diagnosis and treatment can be made by experienced staff.

We can anticipate the development in the next decade of treatments which will stop or slow the progression of Alzheimer’s disease or Parkinson’s disease. Like multiple sclerosis, these treatments will likely be long-term therapies which are very expensive and might also have potentially serious adverse effects, making early and accurate diagnosis just as important as in stroke and multiple sclerosis. Enhancements in diagnosing these disorders will likely include new types of brain scans which detect amyloid plaques of Alzheimer’s disease or identification of biomarkers in the blood or spinal fluid which facilitate early detection of Alzheimer’s disease, Parkinson’s disease and other disorders.

In its *Blue Sky Vision for the Future of Neuroscience*, the National Institutes of Health (NIH) and National Institutes of Neurological Disorders and Stroke (NINDS) identified infrastructural and technological needs for the next 15 years, including determining individuals’ risk for specific diseases based on genomic markers, developing anatomical



John Schafer, MD

continued on page 3



For your convenience in neurological admissions, a dedicated toll-free number is available 24/7:

1.888.MERCY41
(1.888.637.2941)

Mercy Neurological Institute *Synapse* Editorial Board

John Schafer, MD
Neurologist
Editor in Chief
Mercy Neurological Institute

Brian Ivie
President/CEO
Mercy San Juan Medical Center

Robynn Gough-Smith, RN
Regional Director
Mercy Neurological Institute

Alan J. Shatzel, DO
Neurologist
Mercy Neurological Institute

M. Asim Mahmood, MD
Medical Director, Neurology and Neurovascular Medicine

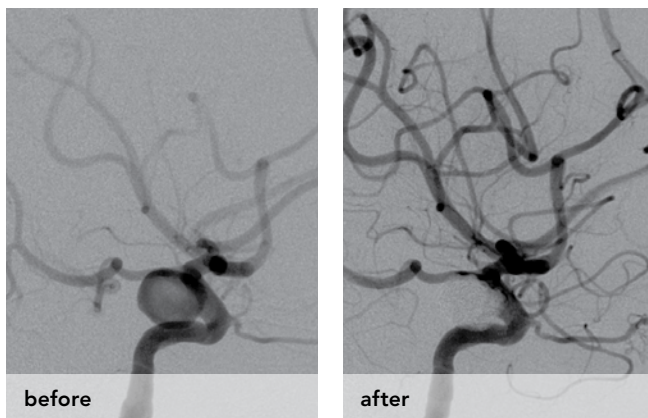
George Luh, MD
Medical Director, Interventional Neuroradiology

Kavian Shahi, MD, PhD
Medical Director, Neurosurgery

Novel Brain Aneurysm Treatment, continued from page 1

(>4mm) or dome to neck ratio of <2 that are not amenable to surgical clipping.

Onyx is an ethylene vinyl alcohol copolymer dissolved in the organic solvent dimethyl sulfoxide (DMSO). When Onyx contacts an aqueous solution, it precipitates and forms a soft spongy polymer cast. This material offers complete volumetric filling of the aneurysm, whereas treatment of an aneurysm with coils offers approximately 30 percent volumetric filling. Improved volumetric filling of the aneurysm offers new hope to patients with wide neck aneurysms and hopefully will significantly reduce the recurrence rate.



The before and after pictures are from the first patient in Northern California outside the Bay Area treated with Onyx HD 500. She is a 75-year-old female with a large unruptured left posterior communicating artery aneurysm. The images demonstrate complete occlusion of the aneurysm and preservation of the adjacent vessels. She was observed overnight and discharged the following day without any complications. At home she continues to do well and is very happy overall with her treatment.

Technological advances in the treatment of brain aneurysms include the development of bioactive coils, ultra soft coils, 3-D coil shapes, stretch-resistant coils, hydrogel-coated coils, intracranial stents, flow diverters, balloon remodeling and liquid embolic agents such as Onyx HD 500. Researchers at the Mercy Neurological Institute of Greater Sacramento are dedicated to the continuing advancement of brain aneurysm treatment. Current on-going clinical trials here at the Mercy Neurological Institute include the HydroCoil versus Cerecyte Aneurysm treatment Trial (HCAT). This study is a prospective randomized trial comparing a hydrogel-coated coil, HydroCoil, with a bioactive coil, Cerecyte. The primary endpoint is aneurysm recurrence rate at 12 to 18 months and treatment-related morbidity and mortality. 🏥

Letter from the Editor, continued from page 2

and functional scans which can be used to screen, prior to onset of manifestations of disease and to enhance access to neurological care through telemedicine.

Mercy Neurological Institute is already on the forefront with emergency stroke care via a telemedicine robot to Mercy Hospital of Folsom. Other outlying hospitals are expected to “go online,” and plans are under way to provide other services, including multiple sclerosis care, to individuals in remote areas through telemedicine services. A detailed description of Mercy’s telemedicine program is found in this issue of *Synapse*.

The past two decades’ progress in diagnosis and treatment of neurological disorders has been breathtaking, but is

only a taste of what’s to come. I’m pleased to be a part of Mercy’s team of dedicated neuroscience professionals bringing these advances to the Sacramento region and beyond. It’s exciting to consider the impact such technology, deployed in a collaborative model, can have on people who might otherwise have died or lived less fulfilling lives due to conditions such as Alzheimer’s and Parkinson’s disease.

I am pleased to share updates on these technologies, treatments and outcomes with my colleagues through this first and all futures issues of *Synapse*.

If you have general comments or interest in future topics, I’d love to hear from you. Please e-mail me at mercyneuro@chw.edu. 🏥



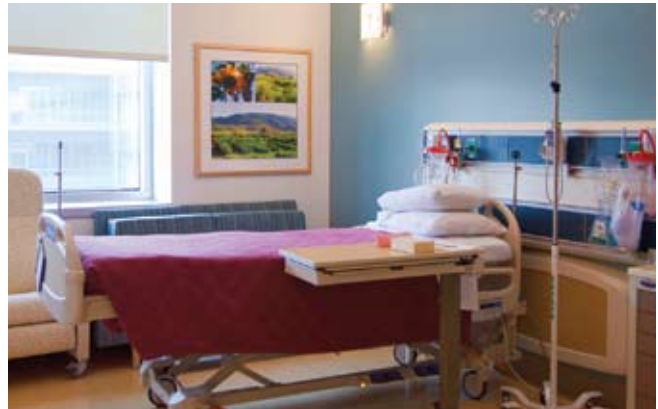Mercy San Juan Medical Center: New Patient Tower

A Towering Investment in Neurological Care

Mercy San Juan's recent construction of the 110-bed patient tower has answered the call for more hospital beds in the Sacramento community. Significantly, 15 of those beds will be in private rooms dedicated to neurological care.

Research shows that having dedicated neurology or stroke units improves outcomes by as much as 19 to 25 percent. There are many contributing factors, but a key element is the familiarity of the nursing staff with neurology patients and the physicians, and their knowledge of the types of therapies that are most beneficial to the patients. Nurses and physicians on these units have the ability to recognize changes in these patients and recognize them quickly.

"A subtle change in heart rhythm and blood pressure, for instance, may be an indication of increased intracranial pressure in a stroke patient," explains M. Asim Mahmood, Medical Director of Neurology and Neurovascular Medicine. "This needs to be dealt with immediately or it could lead to a critical situation, even death. Clinicians who work with these patients every day will have a greater likelihood of noticing such changes and taking the necessary steps to give the patient the best chance for recovery." In



Dr. Mahmood's view, the commitment of 15 beds to neurological care is a valuable investment that will pay great dividends for its patients.

The tower's added beds will also ease waiting times in Mercy San Juan's bustling emergency department and give surgery and cardiac patients spacious, private rooms for recovery. Carefully designed with the latest innovations in hospital room technology and resource efficiencies, the new tower will provide an enhanced healing environment for Mercy's patients and family members. 🏥

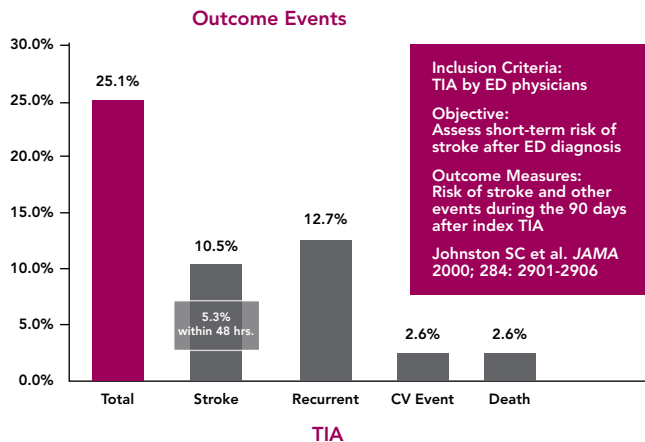


Interested in receiving *Synapse* electronically? Register today at mercyneuro.org.

MMG Neurology Division TIA Clinic

M. Asim Mahmood, MD

TIA: A transient ischemic attack is a focal neurologic deficit that affects the patient transiently without causing permanent damage to the brain. TIAs increase the risk of subsequent strokes reflected by clinical evidence as shown below:



This makes the need for early risk factor stratification and modification imperative.

Risk stratification model (ABCD2): Recent research has helped develop risk stratification models to identify patients at high risk of developing stroke within the first few weeks after suffering from a TIA.

Age > 60 years (1)	S	6-7 — Admit
BP: SBP > 140, DBP > 90 (1)	C	4-5 — or
Clinical $\left\{ \begin{array}{l} \text{Unilateral weakness (2)} \\ \text{Speech impairment (1)} \end{array} \right.$	O	
Diabetes Mellitus (1)	R	0-3 — TIA Clinic
Duration > 60 min (2); 10-50 min (1)	E	

TIA clinic launches: Current clinical evidence suggests that patients with TIAs have a significant improvement in risk factor modification as well as stroke risk when provided specialized care in a modality-specific clinic setting. A significant proportion of these patients can potentially be triaged to early outpatient follow-up using the model described. The purpose of a TIA clinic is to provide early

intervention for minimizing stroke risk in these high-risk patients with the help of risk factor modification and patient/caregiver education.

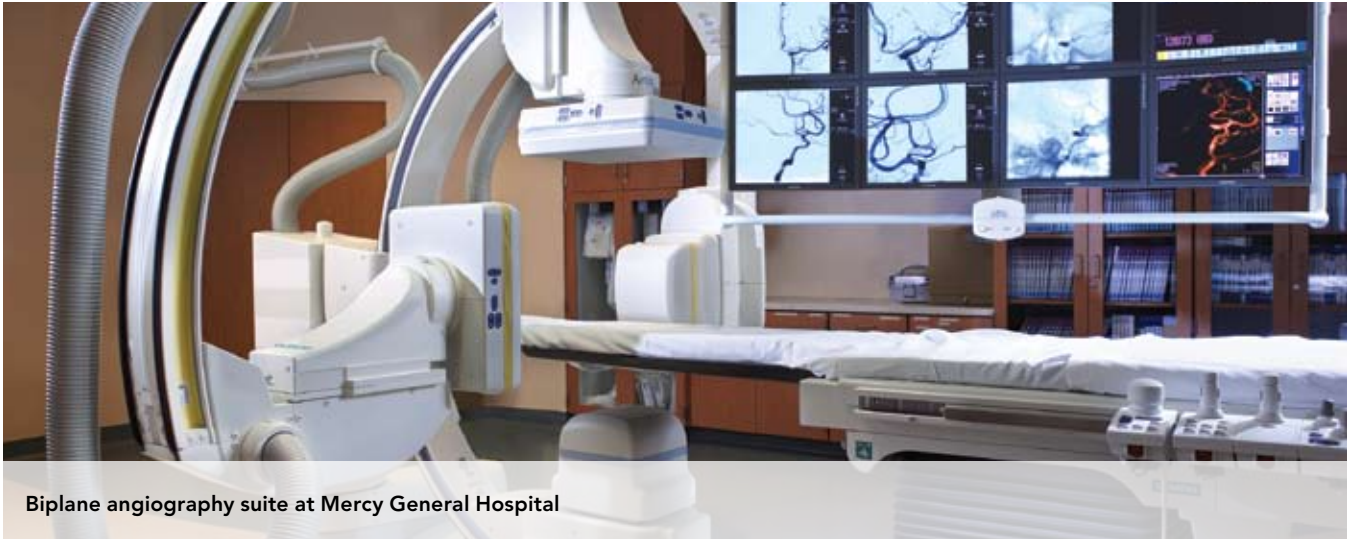The recently launched TIA clinic at Mercy Medical Group is the first of its kind in the area. The philosophy of the clinic is to provide the patient with quality differential service that would avoid duplication and enhance the utilization of specialty resources. The objectives of the clinic are:

- Rapid and seamless access to outpatient neurologist from the ER, hospital, referring physician or community
- Bundling of diagnostic work-up even before the patient arrives at the clinic
- Confirmation of the diagnosis, personalized discussion between the patient and the specialist on diagnosis and initiation, modification or continuation of appropriate therapy
- One-on-one education on TIA, stroke, risk factors and their management as well as increasing awareness; also, provision of published education material and description of available resources
- Enrollment in the Heart Smart program at Mercy, for follow-up on control and management of risk factors
- Follow-up communication with patient's primary and/or referring physician

Logistic considerations: Hospitals, ERs or physician offices from outside of the Mercy group will be able to refer patients by calling 1.888.MERCY41. The stroke coordinator at Mercy will receive the information, help triage patients urgently to the clinic and schedule a one-day diagnostic visit at Mercy. Currently the clinic has been scheduled for Wednesday afternoons as part of the vascular neurology service. Some patients could be scheduled Monday afternoons as needed. 🏥



M. Asim Mahmood, MD



Biplane angiography suite at Mercy General Hospital

Mercy Launches Two Advances in the Treatment of Brain Aneurysms

The Mercy Neurological Institute of Greater Sacramento is the first in the Sacramento region to offer a new minimally invasive aneurysm treatment procedure and a new technology that helps confirm an aneurysm has been successfully clipped during brain surgery.

Onyx HD500

Kyoko Ellis, 75, was diagnosed with an unruptured aneurysm early fall 2009. The aneurysm's shape was unusual with a wide neck, which can be challenging during endovascular therapy. Aneurysms with a wide neck present challenges to coiling and often a stent is deployed across the neck of the aneurysm to help hold the coils in place. A recent advance in the endovascular treatment of brain aneurysms involves filling the aneurysm with Onyx HD500, a thick, non-adhesive glue that can completely plug up a wide-neck aneurysm.

The Onyx HD500 procedure is similar to the coiling procedure but instead of using coils, the Onyx HD500 is injected directly into the aneurysm through a small, thin micro-catheter while the bottom or base of the aneurysm is temporarily sealed with a separate balloon-tipped catheter.

George Luh, MD, Medical Director of Interventional Neuroradiology at the Mercy Neurological Institute, suggested using Onyx HD500 to treat Kyoto Ellis' aneurysm.

"He told me it was a new treatment but it was approved by the FDA (U.S. Food and Drug Administration) and I didn't have to worry about it," said Ellis. "Dr. Luh cares for his patients and his work, so I trusted his opinion that for my case, this new liquid was much better."

Aneurysms with a wide neck present challenges to coiling and often a stent is deployed across the neck of the aneurysm to help hold the coils into place.

Ellis went home the day after surgery at Mercy General Hospital without any complications. She was the first patient in the Sacramento region to be treated with Onyx HD500 which is currently offered only at the Mercy Neurological Institute. Since Ellis' treatment, three other patients have been successfully treated with Onyx HD500 without complication.

IR 800 Fluorescent Angiography

The Mercy Neurological Institute is also breaking ground in neurosurgery and the treatment of aneurysms. The new technology, fluorescent angiography, allows neurosurgeons to quickly view blood flow in blood vessels in better detail

continued on page 7

to assess whether aneurysms have been adequately clipped during brain surgery.

Paz Saroa ignored the painful headaches she was experiencing for two weeks until Sept. 24, when she felt dizzy while moving furniture. She says her head started to hurt. "I couldn't stand the pain. I took a shower hoping it would go away," Saroa said. "It didn't help, so I called 911."

Kavian Shahi, MD, PhD, Medical Director of Neurosurgery at the Mercy Neurological Institute, determined Saroa had a burst aneurysm and that she needed neurosurgery to clip the aneurysm and stop it from bleeding. During the surgery, Dr. Shahi used IR 800 fluorescent angiography to make sure he clipped the aneurysm correctly and that blood was flowing in the brain.


The technology utilizes a fluorescent dye that is given intravenously, and when viewed on a surgical microscope, gives neurosurgeons a clear view of blood flow.

As one of the most important advances recently made in the field of neurosurgery, fluorescent angiography can help reduce complications such as stroke during surgery. It confirms that the aneurysm has been addressed and makes sure the brain is getting sufficient blood supply.

Until now, neurosurgeons have relied on angiograms as a postoperative check. The IR 800 helps neurosurgeons more quickly recognize and address complications associated with surgical clipping of aneurysms during surgery.

Saroa was released from the hospital on her 48th birthday. She's taking life a little slower during her recovery and is pleased with her care. "I'm 100 percent happy."

The Mercy Neurological Institute is the first to offer IR 800 fluorescent angiography in Sacramento. 🏥

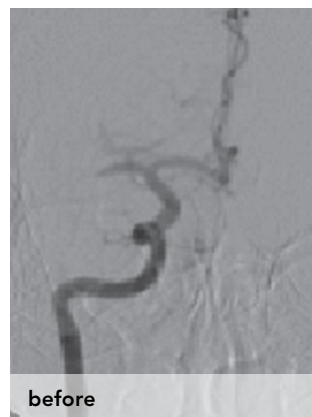

Kavian Shahi, MD, PhD

At the Forefront of Acute Stroke Intervention

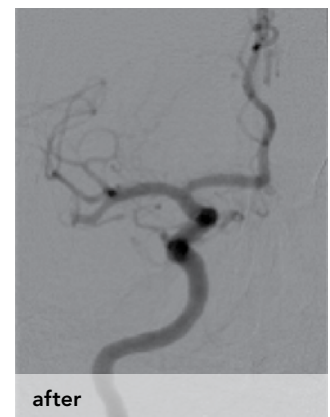
George Luh, MD

Time is brain. Every second counts when the brain suddenly becomes deprived of blood. Recent advances in neurointervention continue to improve acute stroke therapy. Penumbra, Inc. has come out with a new larger aspiration catheter that allows 4x the aspiration rate of the previous microcatheters. The Penumbra System is designed to revascularize large vessel occlusions in the intracranial circulation by using a unique microcatheter and Separator™ wire-based thrombus debulking approach. This translates into faster clot removal and earlier brain reperfusion, which could lead to better patient outcomes. The Mercy Neurological Institute is proud to be the first in Northern California to use this new improved microcatheter.



before

Initial angiogram shows proximal right Middle Cerebral Artery (MCA) occlusion.



after

Follow-up angiogram taken 10 minutes later shows recanalization of the proximal MCA. (A major distal MCA branch remains occluded, but this was also later recanalized.)

The patient initially presented with left hemiplegia, left facial droop, left hemianopsia, a right gaze preference, and a NIHSS of 18. Two days later, his NIHSS improved to 11. Overall, since his procedure, his motor function, sensation and vision have improved. 🏥

Robotic Telemedicine

Alan Shatzel, DO

Mercy Neurological Institute uses remote presence technology to speed access to our interdisciplinary team of stroke care experts to improve safety, efficacy and outcomes for patients.

The term “telemedicine” derives from the Greek “tele” meaning “at a distance” and the Latin “mederi” meaning “healing.” The term was first coined in the 1970s by Thomas Bird, referring to healthcare delivery where physicians examine patients from a distance through the use of telecommunications technologies.

Centers for Medicaid & Medicare services (CMS) define telemedicine as:

“The use of medical information exchanged from one site to another via electronic communications to improve a patient’s health. Electronic communication means the use of interactive telecommunications equipment that includes, at a minimum, audio and video equipment permitting two-way, real time interactive communication between the patient, and the physician or practitioner at the distant site.”

The European Commission’s healthcare telematics programme defines telemedicine as:

“Rapid access to shared and remote medical expertise by means of telecommunications and information technologies, no matter where the patient or relevant information is located.”

Telemedicine is not a new concept. We use telehealth technology on a daily basis. The exchange of information that happens between two people can actually happen in real time using synchronous and asynchronous technologies. Mercy Telehealth Network allows us to compress time and space, placing our stroke care specialist at the bedside of the patient within minutes of receiving a call. Distance is no longer a limiting factor in ensuring patients receive the right care, at the right time, every time.

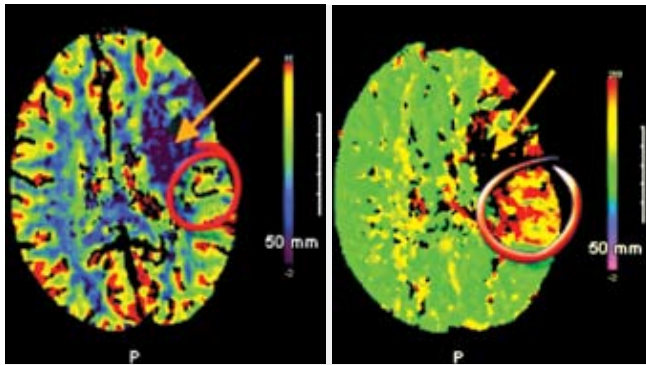
Distance is no longer a limiting factor in ensuring patients receive the right care, at the right time, every time.

Mercy Telehealth Network

Mercy Neurological Institute of Greater Sacramento is developing a TeleStroke Neuroscience Network. The technology allows our expert team of stroke care specialists to provide bedside consultative services and decision support for hospitals and emergency room doctors who’ve traditionally been left without neurological service coverage, therefore limiting their ability to provide medical therapies and interventions to improve outcomes and speed recovery for patients.

continued on page 9





Advanced CT Imaging of brain using 64 slice (Siemens Somatom) CT Perfusion. Orange arrows represent ischemic core (non-salvageable tissue). Circled regions represent “stunned” brain cells—salvageable neurons.

Case Example/Clinical Scenario

M.W. is a 54-year-old right-handed gentleman who developed acute onset of right-sided weakness and difficulty speaking. These symptoms were recognized by co-workers as a possible stroke and they called 911. M.W. was transported to the closest stroke care facility arriving about 10 minutes after the onset of symptoms. Upon arrival, the patient was identified as a probable acute stroke patient and the Mercy Stroke Team was activated. Using remote telepresence (robotic) technology, Mercy Stroke Centers’ on-call hospital-based stroke neurologist was able to assess M.W. in less than 10 minutes of his arrival. Interventions for acute stroke are time intensive and intravenous thrombolytic therapy must be delivered within three hours of stroke onset and ideally within 60 minutes of arrival at the emergency room. The patient was evaluated for exclusion criteria to medical therapy and all lab data, imaging studies, recent history and current vital signs were reviewed. There were no identified exclusions to therapy and the patient met all inclusion criteria; therefore, the patient received intravenous recombinant Tissue Plasminogen Activator (r-tPA) which is standard medical therapy for acute ischemic stroke.


Mercy’s stroke neurologist was at the bedside, in a virtual sense, within minutes by using two-way AV technology and a remote controlled robot. Using our remote presence technology the patient received the best care possible from an experienced stroke neurologist by using a central control station at our base hospital nearly 15 miles away.

M.W. was transferred to our tertiary stroke care center for further evaluation and management. Upon arrival to our center, the patient was evaluated with advanced imaging technology including CT angiogram and CT perfusion. A large clot was identified in the proximal left middle cerebral artery and the patient was a potential candidate for neurovascular intervention. He underwent successful neurovascular intervention and reperfusion of “stunned” neurons which significantly improved his motor and language recovery. He was discharged from Mercy Acute Rehabilitation with only mild motor deficits and significant recovery of his language.

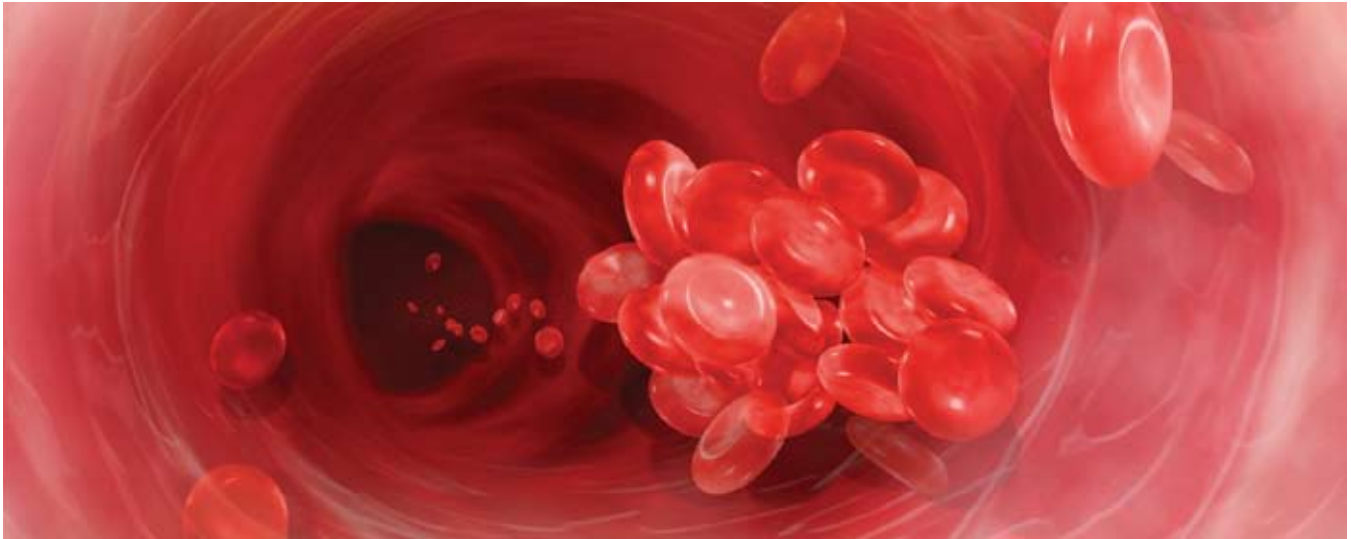
Mercy Neurological Institute of Greater Sacramento

The Mercy TeleStroke Neuroscience Network is one example of our commitment to improving care for patients affected by neurological disease. We are committed to investing in innovative technologies so that patients can benefit from our experience, knowledge and skill in caring for complex neurological or neurosurgical conditions. Our dedicated team of experts in neurology, neurosurgery and interventional neuroradiology are supported by advanced nurse specialist/stroke coordinators’; specially trained nurse practitioners, technical experts and dedicated neuroscience/rehabilitation nursing.

Outreach and knowledge-based support for hospitals and emergency departments is accomplished through remote telepresence (robotic) technology via telemedicine. Mercy Neurological Institute’s development of the Mercy Telehealth Network is improving safety, efficacy and recovery for patients affected by neurological disease. +



Alan Shatzel, DO



The Pursuit of Knowledge

Research Opportunities through the Mercy Neurological Institute

Mercy has participated in over 30 national and international multicenter trials in acute stroke treatment and stroke prevention since the early 1990s. Our current research team includes neurology, neurosurgery, interventional neuroradiology and rehabilitation specialists, and five research coordinators. Here is a list of protocols currently under way.

Carotid Occlusion Surgery Study (COSS)—NIH/NINDS sponsored (open for enrollment)

The purpose of the study is to see if treatment of a high-risk group of patients (poor cerebral blood flow and high oxygen extraction fractions as determined through PET) will have lower stroke risks if they undergo Extracranial and Intracranial (EC/IC) bypass. EC/IC bypass is basically a “brain bypass” procedure, which forms an anastomosis of the superficial temporal artery to a branch of the middle cerebral artery to provide additional collateral circulation pathway. Patients will be randomized to either best medical therapy or surgery.

Principal Investigator: M. Asim Mahmood, MD, Medical Director, Neurology and Neurovascular Medicine

Randomized Evaluation of Carotid Occlusion and Neurocognition (RECON)—NIH/NINDS sponsored (open for enrollment)

Substudy of the COSS protocol. The goal of this study is to test the hypothesis that patients who have symptomatic, unilateral carotid occlusion and stage II cerebral hemodynamic failure will have better cognitive function following EC/IC bypass compared to an identical group of patients treated with best medical therapy.

Principal Investigator: M. Asim Mahmood, MD, Medical Director, Neurology and Neurovascular Medicine

Clot Lysis: Evaluating Accelerated Resolution of Intraventricular Hemorrhage Phase III (CLEAR III)—NIH/NINDS sponsored (open early 2010 for enrollment)

The purpose of this clinical trial is to compare a policy of early extraventricular drain (EVD) use and recombinant tissue plasminogen activator (r-tPA) with EVD use and placebo (normal saline) in the treatment of patients with intracerebral hemorrhage (ICH) and intraventricular hemorrhage (IVH) with obstruction of the third or fourth ventricles by blood. The primary aim is to observe patient outcomes at six months in both groups.

Principal Investigator: Kavian Shahi, MD, PhD, Medical Director, Neurosurgery

continued on page 11

**Interventional Management of Stroke III (IMS III)—
NIH/NINDS sponsored (open early 2010 for enrollment)**

This study will compare a combined intravenous (IV) and intra-arterial (IA) treatment approach to restoring blood flow to the brain during an ischemic stroke, to the current standard FDA approved treatment approach of giving IV r-tPA alteplase, Activase alone. Both approaches must have treatment initiated within three hours of stroke onset. Mechanical thrombectomy (clot removal) devices are allowed to be used in conjunction with the IA r-tPA. The primary outcome is functional outcome/independence at three months in both groups.

Principal Investigator: M. Asim Mahmood, MD,
Medical Director, Neurology and Neurovascular Medicine

**HydroCoil Cerecyte Aneurysm Treatment Trial (H-CAT)—
sponsor: MicroVention Terumo (open for enrollment)**

This is a prospective randomized trial comparing the MicroVention HydroCoil Embolic System (HES) with the Micrus Cerecyte (polymer loaded) coils for the treatment of aneurysm. Both of these coils are FDA approved and in common use at institutions both in this country and in


Europe. The primary aim of this study is to determine the occlusion rate following treatment, and secondary aims are to note the packing density of the aneurysm and clinical outcome of the patients at six and 12 months.

Principal Investigator: George Luh, MD,
Medical Director, Interventional Neuroradiology


**Penumbra Imaging Collaborative Study (PICS):
A Multicenter Trial to Assess Outcome of Patients
Revascularized by the Penumbra System™ (open early
2010 for enrollment)**

This is a prospective, post-marketing, observational study of patients who receive treatment of their acute ischemic stroke with the Penumbra Clot Retrieval System. The main objectives of this study are to determine the proportion of patients with revascularization of the target vessel and the 90-day functional outcome.

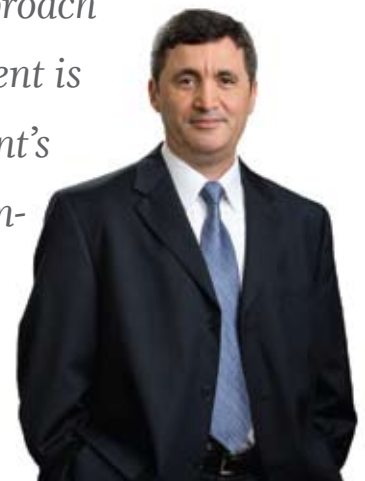Principal Investigator: George Luh, MD,
Medical Director, Interventional Neuroradiology

For any questions regarding any of these trials, please contact Deidre Wentworth, RN, Regional Manager, Mercy Neurological Institute at 916.453.4233. 

**Mercy Welcomes New Physician,
El-Hadi Mouderrres, MD**

Mercy Neurological Institute of Greater Sacramento is pleased to announce the latest addition to the team. El-Hadi Mouderrres, MD is board certified in neurology with special training in clinical neurophysiology-epilepsy and intra-operative monitoring. His practice will be with Nidal Khalili, MD at Methodist Hospital of Sacramento. Contact Dr. Mouderrres at 916.681.9401. 

“We manage epilepsy with a comprehensive approach because every patient is special. Each patient’s treatment is custom-made according to their needs and specificity.”



El-Hadi Mouderrres, MD



PRSR
FIRST-CLASS
US POSTAGE
PAID
SACRAMENTO CA
PERMIT NO 333

MERCY NEUROLOGICAL INSTITUTE
OF GREATER SACRAMENTO

3400 Data Drive
Rancho Cordova, CA 95670

MERCY GENERAL HOSPITAL
MERCY HOSPITAL OF FOLSOM
MERCY SAN JUAN MEDICAL CENTER
METHODIST HOSPITAL OF SACRAMENTO
SIERRA NEVADA MEMORIAL HOSPITAL
WOODLAND HEALTHCARE

Interested in receiving *Synapse* electronically?
Register today at mercyneuro.org.

MERCY NEUROLOGICAL INSTITUTE OF GREATER SACRAMENTO

UPCOMING EVENTS

Join us monthly for Neuro Grand Rounds

Mercy General Hospital

First Thursday of each month at 12:30 p.m.

Mercy San Juan Medical Center

First Friday of each month at 12:30 p.m.

February's topic features an update on headache management presented by Marc Lenaerts, MD, FAHS, Neurologist and Headache Specialist.

Questions or program suggestions can be directed to Candy Collins, CHW CME Office at 916.733.6334.

Save the Date: Insights & Innovations

Mercy's annual evening CME event, Insights & Innovations, is scheduled for May 6 at Arden Hills Country Club. Mark your calendar and visit mercyneuro.org for more information.